Thematic Review Series

Respiration

Respiration 2004;71:107–119
DOI: 10.1159/000076670

Diagnostic Invasive Procedures in Diffuse Infiltrative Lung Diseases

Venerino Poletti[a,b] Marco Chilosi[c] Dario Olivieri[b]

[a]Dipartimento di Malattie dell'Apparato Respiratorio e del Torace, Ospedale GB Morgagni, Forlì,
[b]Dipartimento di Scienze Cliniche, Sezione di Clinica Pneumologica, Università di Parma, Parma, e
[c]Dipartimento di Patologica, Università di Verona, Verona, Italia

Downloaded from http://karger.com/res/article-pdf/71/2/107/3505852/000076670.pdf by RWTH Aachen University user on 06 March 2026

Key Words
Diffuse infiltrative lung disease · Interstitial lung disease · Immunocompromised patient · Bronchoalveolar lavage · Transbronchial lung biopsy

Abstract
The diagnosis of infiltrative diffuse lung disease may require invasive procedures after all noninvasive tools have failed. The clinical context in which these diseases develop and the radiological patterns are crucial for defining the timing and the methods to be used. Immunocompromised hosts are usually acutely ill with fever, cough, shortness of breath, and often with progressive hypoxemia. In this context a prompt diagnosis is necessary to decrease mortality. Bronchoalveolar lavage [especially in cases that show ground-glass attenuation or alveolar opacification in high-resolution CT scan (HRCT)] is the most important invasive procedure allowing the identification of infectious agents, neoplastic elements and characteristic cytological and phenotypical profiles (for drug injury) in the majority of cases. Less frequently transbronchial lung biopsy, transbronchial needle aspiration and biopsy or surgical lung biopsy are necessary. In immunocompetent patients the clinical spectrum of diffuse lung disease is quite broad. Furthermore, in the last two decades HRCT, used in conjunction with clinical and other noninvasive investigative modalities, has increased the accuracy of diagnosis for some diseases without the need of surgical biopsy. Also in these patients bronchoalveolar lavage, frequently in combination with transbronchial lung biopsy, is sufficient to achieve a definitive diagnosis in the majority of cases. Surgical lung biopsy is, however, still relevant in cases with idiopathic interstitial pneumonias. In this article invasive diagnostic procedures in patients with diffuse lung infiltrates are discussed from the perspective of their clinical context and their imaging characteristics.

Copyright © 2004 S. Karger AG, Basel

Previous article in this series: Zompatori M, Bnà C, Poletti V, Spaggiari E, Ormitti F, Calabrò E, Tognini G, Sverzellati N: Diagnostic imaging of diffuse infiltrative disease of the lung. *Respiration* 2004;71:4–19.

Introduction

The diagnostic approach to diffuse lung disease is a step-by-step process and invasive procedures are considered only when other techniques are inconclusive and tissue, cellular elements or alveolar fluid are deemed necessary for a definitive diagnosis or for therapeutic decisions [1]. The key points in discussing the role of these procedures in the clinical setting of diffuse lung disease are

KARGER
Fax + 41 61 306 12 34
E-Mail karger@karger.ch
www.karger.com

© 2004 S. Karger AG, Basel
0025–7931/04/0712–0107$21.00/0

Accessible online at:
www.karger.com/res

Venerino Poletti, MD, FCCP
Dipartimento di Malattie dell'Apparato Respiratorio e del Torace
Ospedale GB Morgagni, Piazzale Solieri 1
IT–47100 Forlì (Italy)
Tel. +39 0563 731362, Fax +39 0563 731461, E-Mail v.poletti@ausl.fo.it/vepolet@tin.it

therefore: (1) when is an invasive procedure useful or necessary, (2) what procedures are available, and (3) in which order should they be scheduled.

These points are still controversial because in the clinical practice so far there are no standardized rules. Furthermore, the true impact of invasive diagnostic tools assessed taking into consideration the pretest diagnostic probability has not been formally evaluated.

A more detailed understanding of correlations between radiographic abnormalities and pathological findings has been achieved since the introduction of the high-resolution computed tomography (HRCT) scan. HRCT has greatly improved the spatial resolution that can be appreciated by chest radiologists and has allowed to define lesions better by means of morphological characteristics and anatomical distribution [2]. This has greatly increased the differential diagnosis potential of imaging tools and HRCT has been proven to be of value in predicting the diagnostic accuracy of invasive procedures [3–5]. After the advent of HRCT in the clinical practice the view that histological evaluation represents the diagnostic 'gold standard' is in fact increasingly questioned [6–8]. In addition, the repertoire of immunological and molecular analyses that can be performed on cells and tissue has been consistently increased; this can significantly improve the diagnostic accuracy on tissue samples obtained by minimally invasive procedures.

The role and the timing of different invasive procedures in the diagnostic workup of diffuse lung diseases may, therefore, be evaluated taking into account the correlations between histological features and the imaging techniques (in particular HRCT) [2, 5] now routinely used.

However, stating that diffuse lung disease embraces those lung disorders that involve infiltration/fibrosis or fluid accumulation in structures of the secondary pulmonary lobule and that the differential diagnosis is extensive and often daunting, the first step is to divide and differentiate between immunocompromised and immunocompetent patients [9, 10]. The diagnostic approach to respiratory disease in the first group of patients remains a challenge for at least three reasons: (1) the increasing frequency of diffuse lung diseases in these patients, (2) the severity with which these lung diseases often flare up, and (3) the opportunity to rely on a number of new laboratory diagnostic procedures.

In immunocompetent patients the diagnostic approach is usually less urgent and the new microbiological laboratory tests have only a secondary role. In fact, in this group of patients only some infiltrative diffuse lung diseases may present acutely: hypersensitivity pneumonitis, drug-induced lung toxicity, pneumonitis related to toxic exposure (e.g., silo filler's disease), acute eosinophilic pneumonia, acute interstitial pneumonia, and cryptogenic organizing pneumonia [11]. Therefore, the controversies still existing in the field are, in this article, tackled by starting from this distinction.

Immunocompromised Hosts

Immunocompromised patients who develop diffuse lung disease are usually acutely ill with fever, cough, shortness of breath, and often with progressive hypoxemia [9, 10, 12]. In these circumstances it can be difficult clinically to distinguish neoplastic infiltration of the lungs or lung involvement due to collagen vascular disease or vasculitis from overhydration, heart failure, opportunist infection and from the toxic effects of antineoplastic chemotherapy. Radiation therapy, graft-versus-host disease (GVHD), acute and chronic rejection, and idiopathic pulmonary disorders (i.e. alveolar proteinosis in neutropenic subjects, diffuse alveolar damage, organizing pneumonia) may also contribute to the development of pulmonary complications in this clinical setting. The prognosis of immunocompromised patients with lung infiltrates is grim when mechanical ventilation is required [13]. A prompt diagnosis seems, therefore, to be crucial for a better survival [14].

Induced sputum has a role only in HIV-positive patients because of its high diagnostic yield in *Pneumocystis carinii* (or *Pneumocystis jirovecii*) pneumonia and tuberculosis [15, 16]. Bronchoalveolar lavage (BAL), especially when the bronchoscope is guided by HRCT scan findings performed a few hours before, is generally of value in diagnosing opportunist infections, alveolar proteinosis, alveolar hemorrhage and capillaritis, lymphomatous or leukemic lung infiltration, carcinomatous lymphangitis, disseminated hematogenous lung metastases, hypersensitivity pneumonitis, eosinophilic pneumonitis or diffuse alveolar damage due to drugs or radiation [17–20]. Specific findings are diagnostic per se: *P. carinii*, acid fast bacilli, direct immunofluorescent test for *Legionella*, intranuclear or intracytoplasmic viral inclusions, *Strongyloides stercoralis* or other parasitic infections, neoplastic cells, intracytoplasmic hemosiderin and a bloody fluid recovered in alveolar hemorrhage, eosinophilia in eosinophilic pneumonia, intracytoplasmic macrovacuoles and intra- and extracellular oil red-positive drops in lipoidic pneumonia, amorphous extracellular PAS-positive and

Downloaded from http://karger.com/res/article-pdf/71/2/107/3505852/000076670.pdf by RWTH Aachen University user on 06 March 2026

Alcian-negative material in alveolar lipoproteinosis, reactive type II pneumocytes collected in pseudopapillae around amorphous extracellular material in diffuse alveolar damage (table 1; fig. 1). The detection of bacteria or viruses or fungi often after having used more sophisticated microbiological investigations is not per se diagnostic of pneumonia. In these cases the distinction between pneumonia or colonization is based on the radiologic aspects and the clinical background [19, 21].

Nonspecific findings in BAL fluid may be used as an adjunct to diagnosis together with an extensive clinical and roentgenological investigation (table 2) [10, 22–24]. In drug- or radiation-related toxicity besides hyperplastic/dysplastic changes of type II pneumocytes and negative microbiological investigations, any type of alveolitis has been described in BAL fluid. However, morphologically activated CD8+ cells indicating a hypersensitivity reaction are the most frequent and suggestive occurrence. Cellular interstitial pneumonitis as clinicopathological manifestation of GVHD in the lungs may be inferred on the basis of negative pertinent microbiological investigations and CD8+ cell lymphocytosis in BAL fluid [24–26].

Application of deep sedation and use of the laryngeal mask appear to be a safe and effective alternative to intubation for accomplishing fiberoptic bronchoscopy with BAL in patients (adults and children) with suspected pneumonia and severe hypoxemia [27–29]. Protected brushing or lavage has a lower diagnostic yield and specificity because they do not allow to correlate microbiological data with the cytological profile detectable in the respiratory airways and brushing is associated with a higher incidence of side effects [19]. HRCT patterns that have been shown to predict a high diagnostic yield of BAL procedure are [10, 18, 23, 26]: alveolar and/or ground-glass opacities (nonspecific patterns observed more frequently in infections, drug-induced toxicity, organizing pneumonia, alveolar hemorrhage and diffuse alveolar damage), 'tree in bud pattern' (more typically observed in bronchiolitis and peribronchiolitis of infectious cause, i.e. tuberculosis, lobular pneumonitis), nodular or reticulonodular pattern with a perilymphatic distribution (typically observed in lymphomatous infiltration and carcinomatous lymphangitis), and escavated nodules (usually of infectious nature) [24, 30]. A conclusive diagnosis is not obtained in the minority by BAL fluid analysis. In these cases transbonchial lung biopsy or even open lung biopsy has to be considered.

Transbronchial lung biopsy (TBB) is a procedure where pneumothorax is a not very frequent morbidity and significant bleeding a more dangerous and frequent side effect (seen however in <3% of cases) [31]. In cases in which a TBB is deemed necessary and is feasible (absence of significant coagulopathy, platelet >50,000) bronchoscopic procedures should be performed under general anesthesia through a rigid bronchoscope or an oro- or nasotracheal tube under fluoroscopic control in order to better control ventilation and bleeding [32]. In this way the bioptic forceps are not passed through the operating channel of the fiberoptic bronchoscope and therefore, the samples, frequently larger than the tip of the forceps, are not crushed (fig. 2). Combined BAL and TBB may also be performed safely in mechanically ventilated patients [33].

Nonspecific pathological changes are common in TBB specimens in these patients but if they are interpreted in

Table 1. Diagnoses feasible on the basis of BAL findings in immunocompromised patients

P. carinii pneumonia
Mycobacteriosis
Legionellosis
Viral pneumonitis (intranuclear and intracytoplasmic inclusions)
Diffuse alveolar damage (reactive type II pneumocytes and amorphous extracellular material)
Alveolar proteinosis
Eosinophilic pneumonia
Alveolar hemorrhage
Epithelial neoplastic cells
Lymphoid atypical cells (cytological or phenotypical aspects)
Myeloid cells

Table 2. Diagnoses feasible on the basis of BAL findings in immunocompetent patients

Dust exposure (asbestos bodies, silica)
Alveolar proteinosis
Lipoid pneumonia
Chronic eosinophilic pneumonia
Acute eosinophilic pneumonia
Diffuse alveolar damage
Alveolar hemorrhage
Langerhans cell histiocytosis
Bronchoalveolar cell carcinoma
Carcinomatous lymphangitis
Hematogenous metastases
Low-grade B cell lymphoma, MALT type
Microlithiasis
Gaucher and Niemann-Pick cells
Intracytoplasmic inclusions in Hermansky-Pudlak disease

Downloaded from http://karger.com/res/article-pdf/71/2/107/3505852/000076670.pdf by RWTH Aachen University user on 06 March 2026

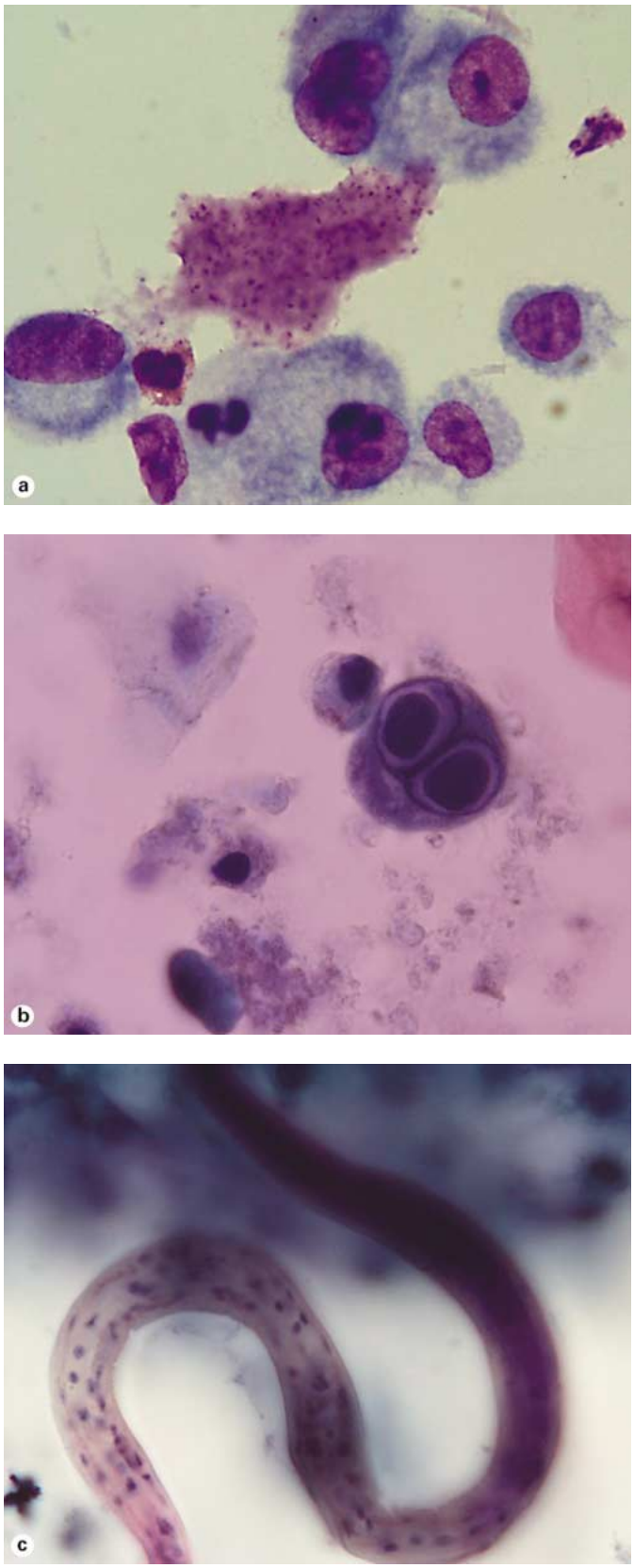



Fig. 2. Big bioptic forceps with a lung sample that is poured out of the tip of the forceps.

the context of a specific clinical setting and of HRCT scan patterns they may contribute to the definition of a specific diagnosis (in particular drug-related lung toxicity, alveolar hemorrhage and vasculitis, alveolar proteinosis) [2, 34]. Also infections may have nonspecific changes as the sole morphological features. Special stains are, therefore, mandatory when TBB specimens are evaluated in immunodepressed patients [34]. Special stains are also useful for the classification of epithelial tumors and mandatory to better identify lymphoid infiltrates (fig. 3).

Needle (transparietal or transbronchial) aspiration of the lungs or of the mediastinal lymph nodes may be helpful mainly in cases in which infectious processes or lymphoproliferative disease are the most likely diagnoses [35, 36].

Surgical lung biopsy (usually via video-assisted thoracoscopy or VATS) is performed in a residual minority of

Fig. 1. a Cluster of *P. carinii* microorganisms. Intracystic sferozoites are well discernable in May-Grunwald-Giemsa-stained preps. **b** Intranuclear inclusion typically due to cytomegalovirus infection. Papanicolaou staining. **c** Filiform larvae of *Strongyloides stercoralis* observed in a patient with hyperinfection. Papanicolaou staining.

Downloaded from http://karger.com/res/article-pdf/71/2/107/3505852/000076670.pdf by RWTH Aachen University user on 06 March 2026

cases. White et al. [37] reported their experience in hematological patients. A specific diagnosis was found in 41 (62%) of the biopsies. The factor most predictive of finding a specific diagnosis was the presence of a focal rather than a diffuse radiographic abnormality. Specific pulmonary diagnoses found were inflammatory diseases in 23% of cases, infections in 21%, and malignancy in 18%. Bronchiolitis obliterans with organizing pneumonia was the most common inflammatory disorder and fungi and bacteria were the most frequent infectious pathogens. Neutropenic patients or those on mechanical ventilation had a low chance of finding a specific diagnosis. Having received pulmonary toxic chemotherapy in the 6 months before the biopsy was associated with finding a nonspecific lung injury [36]. Changes in therapy were made in 57% of patients after biopsy results, but in 69% of those with a specific diagnosis and survival at 30 and 90 days was increased in those with specific rather than a nonspecific pulmonary diagnosis [37]. Complications occurred in 13% of the patients, including 5 patients who required mechanical ventilation after the procedure; one death was associated with the biopsy. The risk was increased in those with less than 50,000 platelets. Complications were similar with VATS compared with thoracotomy.

Some authors have claimed that the lack of impact of invasive diagnostic techniques on survival was the major reason for not performing them in immunocompromised patients [38]. However, a significant decrease in mortality in those patients with an infectious etiology in whom an early diagnosis (7 days from the initiation of the pulmonary infiltrates) caused a change in treatment (29%) compared with those in whom this diagnosis was obtained after 7 days (71%) was found by Rano et al. [39]. The same group has shown that requirement for mechanical ventilation, an APACHE (acute physiology and chronic health evaluation) II score of >20 and again a delay of >5 days in establishing a specific diagnosis were the variables associated with mortality at the multivariate analysis in immunocompromised patients with lung infiltrates.

The added value of TBB in patients undergoing BAL remains contentious. In a retrospective study of immunosuppressed patients TBB was more sensitive than BAL (77 vs. 48% in HIV disease, 55 vs. 20% in hematological malignancy, 57 vs. 27% in renal transplant recipients) and there were few serious complications [40]. In patients with HIV infection it has been argued that a negative BAL result should prompt a repeat BAL with TBB at the most abnormal site; this approach has a diagnostic yield of 90% for nodules or focal infiltrates [41]. In a retrospective study of mechanically ventilated patients, TBB was diagnostic in 35% of cases and led to a change in management in 60% of 'medical' patients and in 25% of patients following lung transplantation [42]. The frequency of pneumothorax was higher (14%) than is generally reported in nonventilated subjects (<5%), but there were no serious complications [42]. At subsequent open lung biopsy or necroscopic examination there was a concordance of 85% with TBB findings. The authors argue [42] that TBB is safe in mechanically ventilated patients with undiagnosed pulmonary infiltrates and may obviate the need for surgical lung biopsy.

The recommendation is, therefore, to use simple noninvasive procedures as a first step in the diagnosis of pulmonary infiltrates in the immunocompromised patient. These noninvasive procedures should include blood antigenemia for specific infectious agents, blood, sputum, and nasopharingeal wash cultures as well as tracheobronchial aspirates in patients on mechanical ventilation. The use of noninvasive techniques leads to the diagnosis in more than 40% of the cases and constitutes a good alternative in those patients with contraindications for a bronchoscopic exploration. Because of the importance of obtaining a diagnosis with minimum delay, BAL should always be performed when possible as this endoscopic procedure has a high diagnostic yield for both infectious and noninfectious etiologies. The use of a protected specimen brush could be avoided since it does not contribute to increasing the diagnostic yield of BAL. Finally, provided no contraindications exist, selected patients should be submitted to needle aspiration or transbronchial biopsies as a step before surgical procedures (fig. 4).

Immunocompetent Subjects

In immunocompetent patients the clinical spectrum of diffuse lung disease is quite broad. Furthermore, in the last two decades HRCT used in conjunction with clinical and other noninvasive investigative modalities has increased the accuracy of the diagnosis for some diseases without the need of surgical biopsy [the majority of cases of idiopathic pulmonary fibrosis (IPF), Langerhans cell histiocytosis, lymphangioleiomyomatosis, silicosis] and HRCT scan patterns with which the disease presents at onset proved very useful in the choice of invasive diagnostic procedures [2, 5–8, 11].

Induced sputum has a subordinate role, being diagnostic in cases of lipoidic pneumonia, eosinophilic pneumonia and, only in skilled hands and in research centers, in

Downloaded from http://karger.com/res/article-pdf/71/2/107/3505852/000076670.pdf by RWTH Aachen University user on 06 March 2026

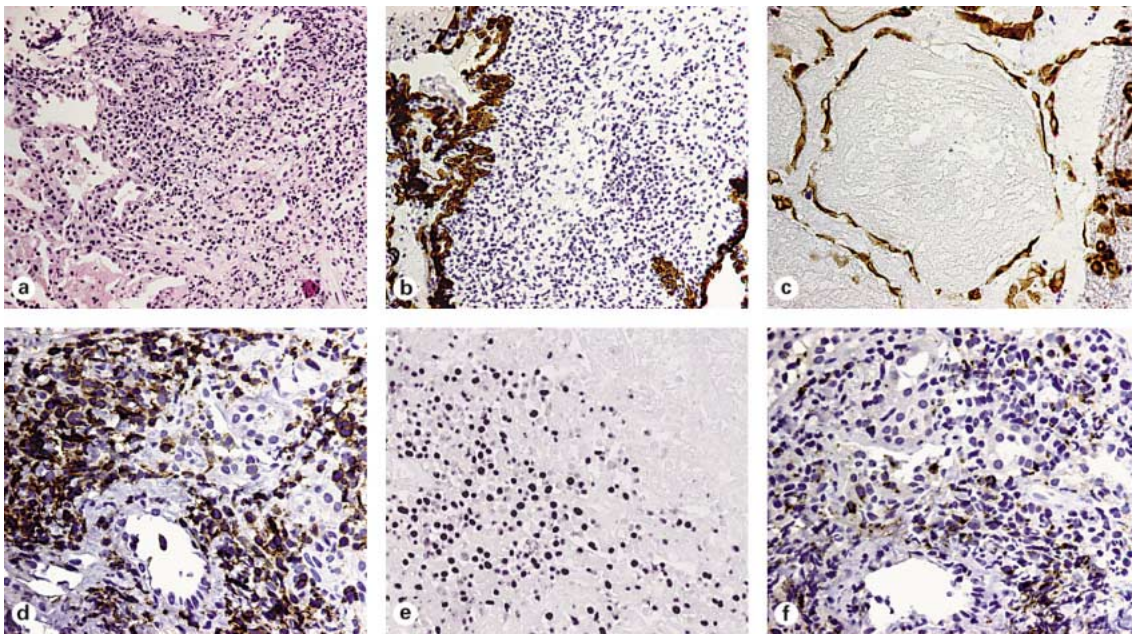

3

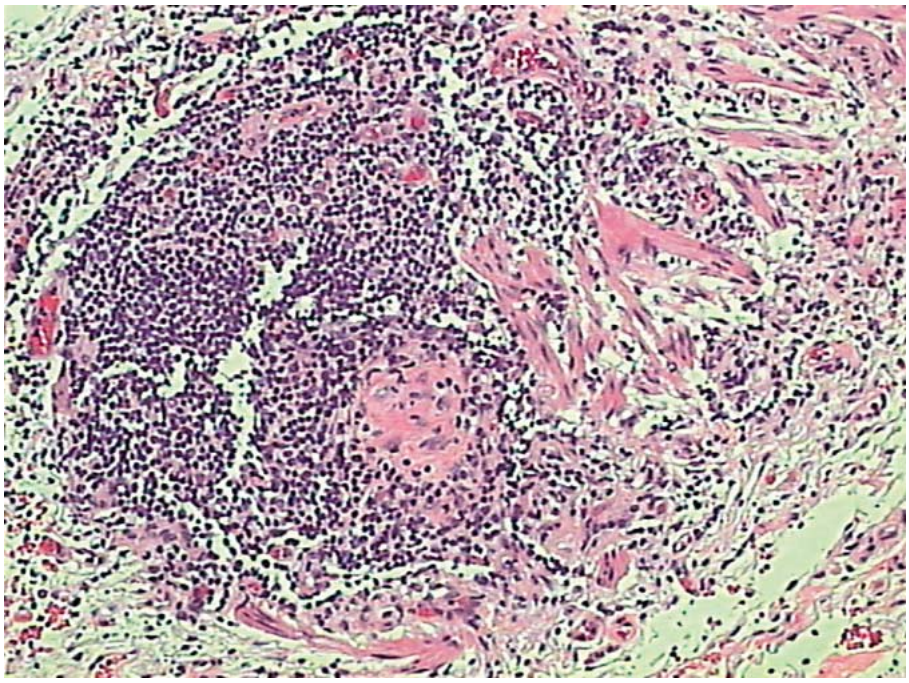

4

Fig. 3. Transbronchial biopsy from a patient with pulmonary T cell lymphoma, nasal type. The precise diagnosis was obtained on scarce material by demonstrating a large lymphoid infiltrate characterized by a T cell, cytotoxic immunophenotype with evidence of EBV infection cells and extensive necrosis. **a** E&E. **b**, **c** Cytokeratin 8/18. **d** CD3. **e** EBER. **f** Granzyme.

Fig. 4. Cellular, lymphocytic bronchiolitis in a patient with GVHD. The lumen of the bronchiole is smaller and the bronchiolar wall is diffusely infiltrated by lymphocytes. Epithelial aggression by lymphoid cells is evident. H&E, mid power.

sarcoidosis when the CD4/CD8 ratio is significantly high [43, 44].

BAL is nowadays considered a milestone in the diagnostic workup of immunocompetent subjects having a diffuse lung disease. There are a few lung diseases in this context in which BAL may provide specific findings that, if present, obviate the need of a biopsy: alveolar proteinosis, dust exposure, eosinophilic lung disease, alveolar hemorrhage, diffuse alveolar damage whatever the clinical context may be (acute interstitial pneumonia, acute exacerbation of IPF, acute respiratory distress syndrome), Langerhans cell histiocytosis, B cell lymphoma of the MALT type (fig. 5), carcinomatous lymphangitis, bronchoalveolar cell carcinoma, lipoidic pneumonia, and rarer

Downloaded from http://karger.com/res/article-pdf/71/2/107/3505852/000076670.pdf by RWTH Aachen University user on 06 March 2026

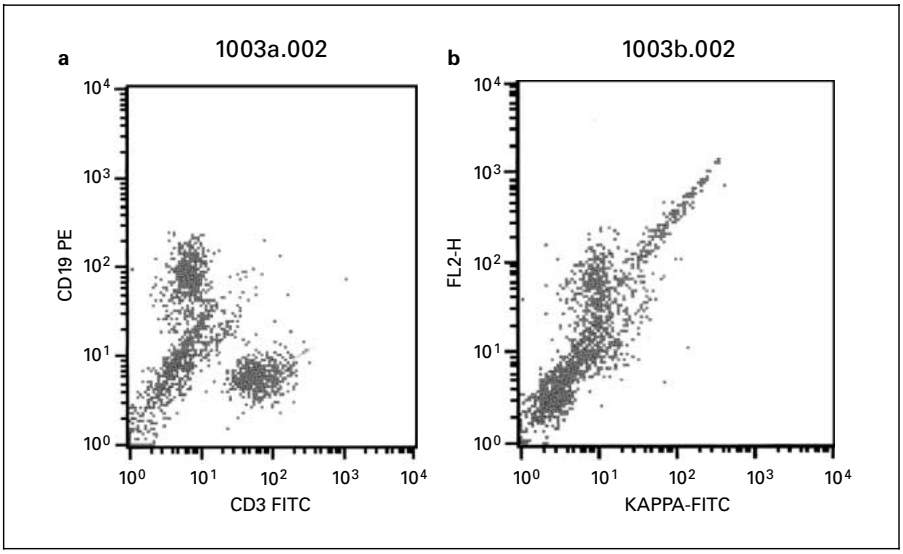

Fig. 5. a BAL. Cytofluorometric analysis showing a significant increase of B lymphocytes (CD19-positive cells). **b** BAL. Cytofluorometric analysis showing a monotypic expression of light chains (lambda chains). Diagnosis: B cell MALT-type lymphoma in the lung.

disorders such as congenital metabolic diseases (Gaucher disease, Hermansky-Pudlak disease) [22, 45–49]. It is noteworthy that many of these disorders are characterized from a pathological point of view by the accumulation of diagnostic cells or extracellular material in the alveolar spaces (the so-called group of alveolar filling diseases) and from a roentgenological point of view by alveolar opacification or ground-glass attenuation on HRCT scan film. The diagnostic yield is very high (almost 100% in alveolar proteinosis and eosinophilic lung disease) except for Langerhans cell histiocytosis in which more than 4% of CD1a+ cells are detected in less than 40% of cases in our institution (and usually in cases with typical nodular and cystic lesions in HRCT scan).

In a number of more numerous diffuse lung diseases, BAL findings are not specific but can be used as an adjunct to diagnosis (table 3). In these conditions BAL analysis may be the key to diagnosis, together with a careful clinical/radiological evaluation, making a biopsy unnecessary in many cases [22]. However, if despite this thorough investigation the diagnosis remains unclear, a biopsy should be considered as the further diagnostic step.

TBB may be considered as the first choice. Andersen et al. [50] are given credit for the first description of TBB following their observation that bronchial biopsy specimens of small airways harvested during the course of rigid bronchoscopy often contained lung parenchyma. TBB forceps reach lung tissue through the bronchial routes and therefore specimens so obtained come from the centrilobular regions [51]. The disorders that are centered around terminal and respiratory bronchioles [respiratory bronchiolitis (RB), tuberculosis, lobular infectious pneumonia, cellular bronchiolitis] or significantly involve these structures (organizing pneumonia) or are distributed along the lymphatic routes (sarcoidosis, carcinomatous lymphangitis) may be easily sampled by the forceps. In 'lymphangitic' disorders bronchial biopsies can also contribute to increasing the diagnostic accuracy [11, 51]. Hypersensitivity pneumonitis in its subacute stage is histologically defined by the presence of peribronchiolar lymphocytic infiltration (cellular bronchiolitis), small ill-defined granulomas, and organizing pneumonia [52]. Generous and numerous TBB specimens may document the presence of this triad and, therefore, be diagnostic. The diagnostic yield of TBB in hypersensitivity pneumonitis varied from a low 20% to more than 90% but this reported broad range of diagnostic yield is likely due to different histological criteria accepted and probably on the number of biopsy specimens collected [53, 54]. Other monomorphous histological patterns (organizing pneumonia, eosinophilic pneumonia, diffuse alveolar damage with or without eosinophils, alveolar hemorrhage with or without capillaritis, alveolar proteinosis) [51, 55] are easily identifiable in small lung fragments but they are more or less nonspecific and are considered diagnostic only in agreement with clinical, radiological and other laboratory data. The tiny specimens obtained by TBB may not be sufficient in cases in which the morphological features are characteristic only in large volumes (usual interstitial pneumonitis, desquamative interstitial pneumonitis, nonspecific interstitial pneumonitis, fibrosing type).

Downloaded from http://karger.com/res/article-pdf/71/2/107/3505852/000076670.pdf by RWTH Aachen University user on 06 March 2026

Table 3. Disease with nonspecific but characteristic BAL profile

Disease	Features
Sarcoidosis	Increased CD4/CD8 ratio [a]
Hypersensitivity pneumonitis	Increased total cell count, lymphocytosis, mast cells, plasma cells, decreased CVD4/CD8 ratio[b]
Organizing pneumonia	Lymphocytosis, scattered neutrophils and eosinophils, plasma cells, decreased CD4/CD8 ratio[b]
Nonspecific interstitial pneumonitis (cellular variant)	Lymphocytosis (decreased CD4/CD8 ratio)
Respiratory bronchiolitis-ILD/desquamative interstitial pneumonitis	Increased total cell count, brown macrophages, slight increase of neutrophils
Giant cell interstitial pneumonitis	Multinucleated giant cell, 'cannibalistic' figures
Bacterial pneumonia	Neutrophils, apoptotic nuclei, intracytoplasmic micro-organisms

ILD = Interstitial lung disease.

[a] CD4/CD8 ratio may also be increased in berylliosis, tuberculosis, asbestosis, Crohn's disease, rheumatoid arthritis.

[b] The differential diagnosis between hypersensitivity pneumonitis and organizing pneumonitis is often not feasible on the basis of BAL features only.

From the morphological point of view the pattern called nonspecific interstitial pneumonia (NSIP), cellular variant is quite characteristic (maintenance of pulmonary architecture, interstitial thickening due to mononuclear cell infiltration, cuboidal type II metaplasia) but it is clinically nonspecific being observed in cases of collagen vascular disease (inflammatory myositis in particular), in patients with drug-related toxicity, in GVHD-related lung damage, and, in a minority of cases, it is of unknown cause (idiopathic NSIP) [56]. Surgical lung biopsy is considered the best way to obtain enough tissue to demonstrate this pattern. However, generous TBB may provide good specimens for a morphological diagnosis. This pathological diagnosis is acceptable in specific clinical settings (polymyositis-dermatomyositis-related interstitial lung disease, drug toxicity) but it might also be of clinical value in cases of unknown etiology [57]. RB is at last easily recognizable in TBB specimens and nowadays the utility of surgical lung biopsy in the diagnosis of RB-associated interstitial lung disease is disputable and probably ethically not advisable.

The role of the number of specimens obtained and of the size of the forceps used has not been evaluated in detail in the literature. Descombes et al. [54] reviewed the histological and clinical data of 530 consecutive TBBs performed in 516 immunocompetent patients, having either a chronic diffuse lung infiltrate, a localized peripheral lung lesion or hilar adenopathies. The authors have shown that there is a direct correlation between the number of samples obtained per TBB and the overall diagnostic yield (i.e. 38% with one to three tissue fragments vs. 69% with six to ten, $p < 0.01$). They recommend that at least five to six specimens per TBB should be taken, the optimal number of specimens to optimize the diagnostic yield being, however, seven to ten. Curley et al. [58] reported that larger biopsy specimens were more likely to contain diagnostic tissue ($r = 0.29$, $p = 0.001$). Cup forceps retrieved smaller pieces of tissue ($p = 0.007$) and were less likely to obtain diagnostic tissue ($p = 0.06$). Specimens that floated were no more likely to be diagnostic or abnormal than specimens that sank ($p < 0.05$). Loube et al. [59] prospectively compared the diagnostic yield of transbronchial biopsies using large and small forceps (cup sizes, $3 \times 2 \times 0.9$ vs. $2 \times 1.5 \times 0.6$ mm, respectively). Large forceps obtained significantly more tissue than did small forceps [20 of 27 patients (74%) vs. 5 of 27 patients (19%), $p < 0.005$]. Also, large forceps obtained significantly more alveolar tissue than did small forceps [16 of 22 patients (73%) vs. 6 of 22 patients (27%), $p < 0.05$, with no alveolar tissue obtained in 5 patients]. If larger forceps are not withdrawn through the operative channel, crash artifacts may also be avoided. Becker et al. [60] and Casoni et al.

Downloaded from http://karger.com/res/article-pdf/71/2/107/3505852/000076670.pdf by RWTH Aachen University user on 06 March 2026

Table 4. Imunohistochemical staining procedures useful to reach a definitive diagnosis on small lung bioptic specimens

Immunophenotypical marker	Recognized cell type	Application
Alpha smooth-muscle actin	Bronchiolar and vessel wall, myofibroblasts	Vascular abnormality, fibroblast foci, Masson's bodies
Bcl-10	Abnormal expression (nuclear)	MALT lymphoma
Beta catenin (nuclear)	Wnt pathway activation	UIP
CD1a	Langerhans cells	Langerhans cell histiocytosis
Langerin	Langerhans cells	Langerhans cell histiocytosis
CD3	T cells	Alveolitis
CD4	T cell subset	Alveolitis CD4+
CD8	T cell subset	Often increased in HP
CD34	Endothelial cells	Vascular abnormalities
CD20	B cells	LIP, B cell lymphomas
CD68	Macrophages	DIP, panbronchiolitis
Cytokeratin 8/18	Epithelial cells (bronchiolar, alveolar)	Alveolar hyperplasia
Cytokeratin 5	Bronchiolar basal cells	UIP, bronchiolization, squamous metaplasia
EBV EBER RNA	EBV infection	Lymphomatoid granulomatosis, nasal-type T cell lymphoma
Granzyme	Activated cytotoxic T cells	T cell lymphoma
Tenascin	Extracellular matrix component	Ongoing fibrosis, fibroblast foci in UIP, Masson's bodies in OP
ΔN-p63	Basal cells in bronchial and bronchiolar epithelia	Bronchiolar proliferation in UIP

UIP = Usual interstitial pneumonitis; HP = hypersensitivity pneumonitis; LIP = lymphocytic interstitial pneumonitis; DIP = desquamative interstitial pneumonitis; OP = organizing pneumonia; EBV = Epstein-Barr virus; EBER RNA = encoded small nuclear early region RNA; MALT = mucosa associated lymphoid tissue.

[32] reported a significant diagnostic yield and/or better preserved specimens when TBBs were performed under general anesthesia using lager forceps and without pulling them through the biopsy channel. A similar technique (the so-called non-pull-through technique) was described by Mullins et al. [61] in small children. Using a plastic suction catheter as the working channel through which biopsy forceps are introduced and an ultrathin (2.2 mm) flexible fiberoptic bronchoscope to direct the catheter visually into the desired lung segment the authors obtained adequate tissue in eight of nine procedures (89%). Specimens obtained through TBB should be serially sectioned and immunohistochemical investigations should be encouraged: Langerhans cell histiocytosis, lymphangioleiomyomatosis, sarcoidosis, carcinomatous or malignant soft tissue metastases, and lymphoproliferative disorders are better defined using specific monoclonal antibodies (CD1a, Langerhin, HMB-45, CD68, TTF-1 or CDX-2 immunohistochemical expression). In the near future probably new markers, identified on the basis of new pathogenetic hypotheses, will be useful to identify pathological lesions also in tiny specimens [62] (table 4; fig. 6). Flexible transbronchial needle aspiration and biopsy, a minimally invasive bronchoscopic procedure increasingly used in the diagnosis and staging of lung cancer, and recently done after endobronchial ultrasonographic inspection, has a role in the diagnosis of diffuse lung diseases when they involve mediastinal lymph nodes at the onset or during the course of the illness (sarcoidosis, mycobacterioses, lymphoproliferative disorders) [36, 63]. Surgical lung biopsy can be carried out via a minithoracotomy or during a VATS. The second option is preferred today because of the larger quantity of tissue obtained and the ability to take biopsy specimens from more than one site [64, 65]. It also reduces the duration of chest tube drainage and length of hospital stay. However, it is not feasible in the presence of severe pleural adhesions or a fused pleural space, or in patients that are not able to tolerate one-lung ventilation. It seems that open lung biopsy for the diagnosis of diffuse lung disease does not

Downloaded from http://karger.com/res/article-pdf/71/2/107/3505852/000076670.pdf by RWTH Aachen University user on 06 March 2026

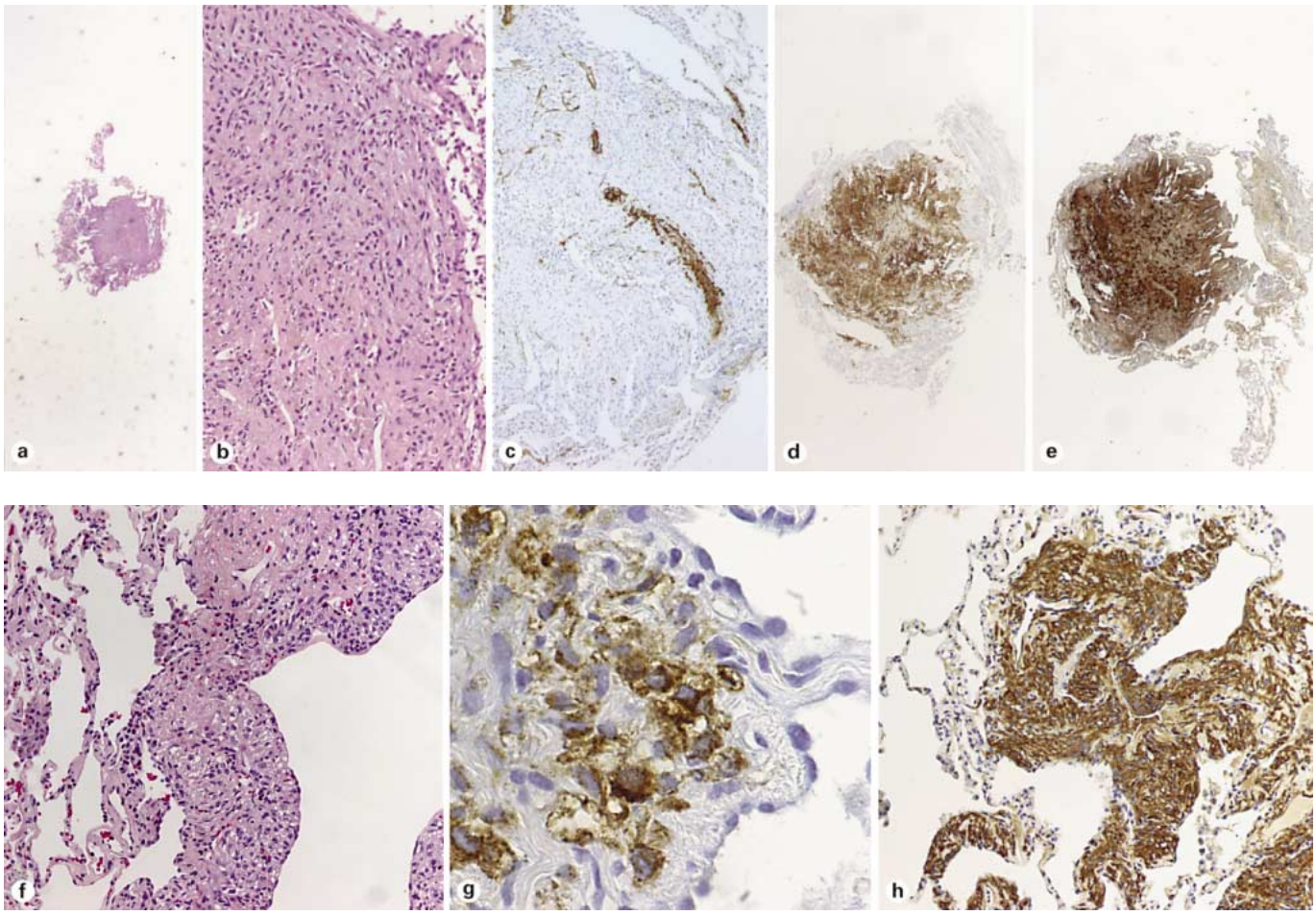

Fig. 6. a–e Transbronchial biopsy obtained from a patient with interstitial lung disease. The immunohistochemical characterization of infiltrating cells revealed a phenotype consistent with the diagnosis of Langerhans histiocytosis. **a**, **b** E&E. **c** a-SMA. **d** CD1a. **e** S100. **f–h** Transbronchial biopsy obtained from a patient with interstitial lung disease. The immunohistochemical characterization of infiltrating cells revealed a phenotype consistent with the diagnosis of lymphangioleiomyomatosis. **f** E&E. **g** HMB-45. **h** a-SMA.

deleteriously affect lung function whether carried out by an open or a minimally invasive procedure [66].

Rules of thumb when a surgical lung biopsy is deemed necessary are:

(1) The site of biopsy should be chosen taking into account the HRCT features. Gaensler and Carrington [67] confirmed that the lingual and middle lobe tip should be avoided because they often show nonspecific fibrosis. This issue is still controversial; two more recent studies which specifically addressed this question did not find any reason to avoid lingular and middle lobe biopsy [68, 69]. Today the points that should be stressed are that HRCT helps clinicians to select the site to biopsy and lobe tips should be avoided since these sites may show nonspecific fibrotic or inflammatory changes. Two specimens should be taken from two different lobes; that is, one from an area of obvious but mild abnormality and one from an area that appears almost normal. Zones of obvious severe fibrotic reaction (honeycomb pattern on HRCT scan) should not be biopsied because the lesions found there would not be helpful in the differential diagnosis.

(2) Surgical lung biopsy specimens should be fixed in inflation.

(3) To ensure that the maximum diagnostic information is obtained a portion of the lung biopsy should be sent to the microbiology laboratory for cultures and smears.

A surgical lung biopsy is necessary for a confident clinicopathological diagnosis of IPF/usual interstitial pneu-

Downloaded from http://karger.com/res/article-pdf/71/2/107/3505852/000076670.pdf by RWTH Aachen University user on 06 March 2026

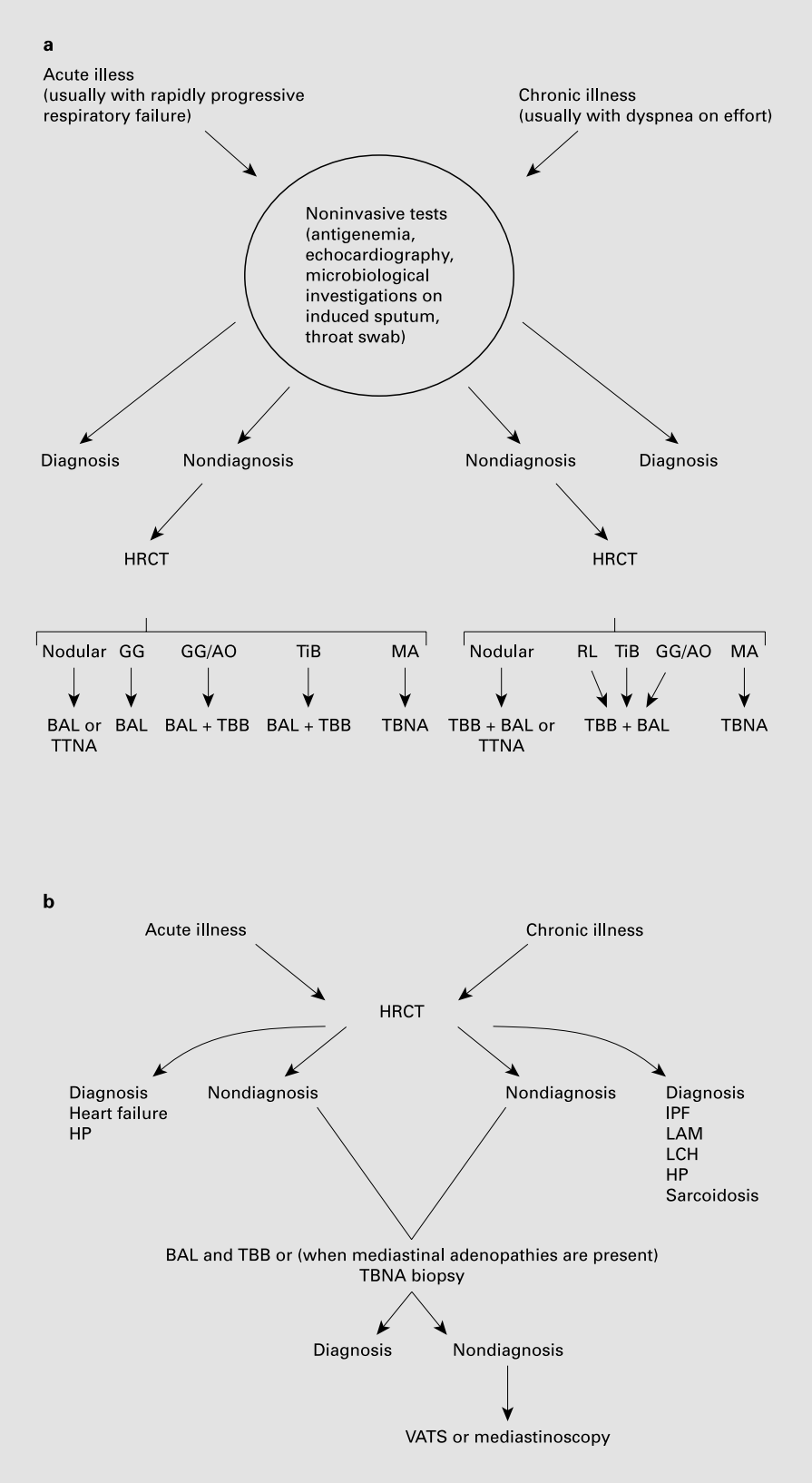

Fig. 7. Algorithm for the invasive procedures in immunocompromised (**a**) and immunocompetent (**b**) patients with diffuse infiltrative lung diseases. **a** GG = Ground-glass attenuation; AO = alveolar opacification; TiB = tree in bud pattern; MA = mediastinal adenopathies; RL = reticulolinear pattern; TBNA = transbronchial needle aspiration and biopsy; TTNA = transthoracic needle aspiration and biopsy. **b** HP = Hypersensitivity pneumonitis; LAM = lymphangioleiomyomatosis; LCH = Langerhans cell histiocytosis.

Downloaded from http://karger.com/res/article-pdf/71/2/107/3505852/000076670.pdf by RWTH Aachen University user on 06 March 2026

monitis in cases with atypical HRCT scan findings, of the NSIP-variant pattern (in the majority of cases of NSIP-cellular variant) or of desquamative interstitial pneumonitis in cases of idiopathic lymphocytic interstitial pneumonitis, to confirm a diagnosis of idiopathic constrictive bronchiolitis, neuroendocrine cell hyperplasia and fibrous bronchiolitis or in rarer forms of infiltrative diffuse lung disease when other procedures have not made possible a definitive diagnosis [11]. Mediastinoscopy is now rarely used in the diagnosis workup of infiltrative diffuse lung diseases. It requires experienced surgeons for optimal results. This procedure is indicated in cases in which mediastinal lymphoadenopathies are evident and when other less invasive procedure have failed. Morbidity and mortality are low but not negligible.

Conclusions

The invasive procedures available during the workup diagnosis of diffuse infiltrative lung diseases are numerous. There are still controversies over the role of these different procedures and the timing of their utilization. However, after the introduction in clinical practice of HRCT scan, the evaluation of imaging patterns, along with the immunological status of the patient and the clinical course of the disease (acute vs. chronic) seem to be crucial to solve the questions mentioned above. An algorithm useful for the practical approach to patients with supposed diffuse infiltrative lung disease is depicted in figure 7.

Downloaded from http://karger.com/res/article-pdf/71/2/107/3505852/000076670.pdf by RWTH Aachen University user on 06 March 2026

References

1 Du Bois RM, Costabel U: Diffuse lung diseases: Classification and diagnostic approach; in Gibson GJ, Geddes DM, Costabel U, Sterk PJ, Corrin B (eds): Respiratory Medicine. Amsterdam, Elsevier Sciences, 2003, pp 1545–1556.
2 Colby TV, Swensen SJ: Anatomic distribution and histopathologic patterns in diffuse lung disease: Correlation with HRCT. J Thorac Imaging 1996;11/1:1–26.
3 Cazzato S, Zompatori M, Burzi M, Baruzzi G, Falcone F, Poletti V: Bronchoalveolar lavage and transbronchial lung biopsy in alveolar and/or ground-glass opacification. Monaldi Arch Chest Dis 1999;54:115–119.
4 Zompatori M, Calabro E, Chetta A, Chiari G, Marangio E, Olivieri D: Chronic hypersensitivity pneumonitis or idiopathic pulmonary fibrosis? Diagnostic role of high resolution computed tomography (HRCT). Radiol Med (Torino) 2003;106:135–146.
5 Muller NL: Computed tomography and magnetic resonance imaging: Past, present and future. Eur Respir J 2002;35(suppl):3s–12s.
6 Hunnighake GW, Lynch DA, Galvin JR, et al: Radiologic findings are strongly associated with a pathologic diagnosis of usual interstitial pneumonia. Chest 2003;124:1215–1223.
7 Remy-Jardin M, Philippe D, Remy J: High-resolution computed tomography techniques in diffuse parenchymal lung disease and their application to clinical practice. Semin Respir Crit Care Med 2003;24:333–346.
8 Wells A: High-resolution computed tomography in the diagnosis of diffuse lung disease. A clinical perspective. Semin Respir Crit Care Med 2003;24:347–356.
9 Jabot-Lestang L, Maitre B, Cordonnier C: Poumons et maladies hématologiques. Encyclopedie Medicochir 2003:1–12.
10 Poletti V, Trisolini R, Tura S: Pulmonary disease in patients with hematologic malignancies. Sarcoidosis Vasc Diffuse Lung Dis 2002;19:29–45.
11 Ryu JH, Olson EJ, Midthun DE, Swensen SJ: Diagnostic approach to the patient with diffuse lung disease. Mayo Clin Proc 2002;77:1221–1227.
12 Pechkam D, Elliott MW: Pulmonary infiltrates in the immunocompromised: Diagnosis and management. Thorax 2002;57(suppl 2):II3–II7.
13 Bach PB, Schrag D, Nierman DM, et al: Identification of poor prognostic features among patients requiring mechanical ventilation after hemopoietic stem cell transplantation. Blood 2001;98:3234–3240.
14 Shorr AF, Kollef MH: The quick and the dead. Chest 2002;122:9–12.
15 Turner D, Schwarz Y, Yust I: Induced sputum for diagnosis of *Pneumocystis carinii* pneumonia in HIV patients: New data, new issues. Eur Respir J 2003;21:204–208.
16 Bell D, Leckie V, McKendrick M: The role of induced sputum in the diagnosis of pulmonary tuberculosis. J Infect 2003;47:317–321.
17 Santamauro JT, Mangino DA, Stover DE: The lung in immunocompromised host: Diagnostic methods. Respiration 1999;66:481–490.
18 Heussel CP, Kauczor HU, Heussel GE, et al: Pneumonia in febrile neutropenic patients and in bone marrow and blood-stem cell transplant patients: Use of high resolution computed tomography. J Clin Oncol 1999;17:796–805.
19 Danes C, Gonzalez-Martin J, Pumarola T, et al: Pulmonary infiltrates in immunosuppressed patients: Analysis of a diagnostic protocol. J Clin Microbiol 2002;40:2134–2140.
20 Rano A, Agusti C, Jimenez P, et al: Pulmonary infiltrates in non-HIV immunocompromised patients: A diagnostic approach using non-invasive and bronchoscopic procedures. Thorax 2001;56:379–387.
21 Pisani RJ, Wright AJ: Clinical utility of bronchoalveolar lavage in immunocompromised hosts. Mayo Clin Proc 1992;67:221–227.
22 Costabel U, Guzman J: Bronchoalveolar lavage in interstitial lung disease. Curr Opin Pulm Med 2001;7:255–261.
23 Soubani AO, Qureshi MA, Baynes RD: Flexible bronchoscopy in the diagnosis of pulmonary infiltrates following autologous peripheral stem cell transplantation for advanced breast cancer. Bone Marrow Transplant 2001;28:981–985.
24 Trisolini R, Stanzani M, Lazzari Agli L, et al: Delayed non-infectious lung disease in allogeneic bone marrow transplant recipients. Sarcoidosis Vasc Diffuse Lung Dis 2001;18:75–84.
25 Palmas A, Tefferi A, Myers JL, et al: Late-onset non-infectious pulmonary complications after allogeneic bone marrow transplantation. Br J Haematol 1998;100:680–687.
26 Cordonnier C, Fleury-Feith J, Escudier E, Atassi K, Bernaudin JF: Secondary alveolar proteinosis is a reversible cause of respiratory failure in leukemic patients. Am J Respir Crit Care Med 1994;149:788–794.
27 Shah S, Mehta P, Stallard NJ: Bronchoscopy with bronchoalveolar lavage via the laryngeal mask airway in high-risk hypoxemic immunosuppressed patients. Crit Care Med 2001;29:1848–1849.
28 Hilbert G, Gruson D, Vargas F, et al: Bronchoscopy with bronchoalveolar lavage via the laryngeal mask airway in high-risk hypoxemic immunosuppressed patients. Crit Care Med 2001;29:2492–2495.
29 Nussbaum E: Pediatric fiberoptic bronchoscopy: Clinical experience with 2,836 bronchoscopies. Pediatr Crit Care Med 2002;3:171–176.
30 Rottoli P, Bargagli E: Is bronchoalveolar lavage obsolete in the diagnosis of interstitial lung disease? Curr Opin Pulm Med 2003;9:418–425.

31 Haussinger K, Kohlauffl MJ, Bolliger CT: Diagnostic bronchoscopy; in Gibson GJ, Geddes DM, Costabel U, Sterk PJ, Corrin B (eds): Respiratory Medicine. Amsterdam, Elsevier Sciences, 2003, pp 415–430.
32 Casoni GL, Bigliazzi C, Vailati P, Gurioli C, Poletti V: Diagnostic value of transbronchial lung biopsy via rigid bronchoscope in diffuse pulmonary disease. Submitted.
33 Bulpa PA, Dive AM, Mertens L, et al: Combined bronchoalveolar lavage and transbronchial lung biopsy: Safety and yield in ventilated patients. Eur Respir J 2003;21:489–494.
34 Katzenstein AL: Transbronchial lung biopsy; in Katzenstein A-LA, Askin FB, Katzenstein A-L, Day L (eds): Katzenstein and Askin's Surgical Pathology of Non-Neoplastic Lung Disease. Philadelphia, Saunders, 1997, pp 442–459.
35 Wong PW, Stefanec T, Brown K, White DA: Role of fine-needle aspirates of focal lung lesions in patients with hematologic malignancies. Chest 2002;121:527–532.
36 Cetinkaya E, Yildiz P, Kadakal F, et al: Transbronchial needle aspiration in the diagnosis of intrathoracic lymphoadenopathy. Respiration 2003;69:335–338.
37 White DA, Wong PW, Downey R: The utility of open lung biopsy in hematologic patients with pulmonary infiltrates. Am J Respir Crit Care Med 2000;161:723–729.
38 Mayaud C, Cadranel J: A persistent challenge: The diagnosis of respiratory disease in the non-AIDS immunocompromised host. Thorax 2000;55:511–517.
39 Rano A, Agusti C, Benito N, et al: Prognostic factors of non-HIV immunocompromised patients with pulmonary infiltrates. Chest 2002; 122:253–261.
40 Cazzadori A, Di Perri G, Todeschini G: Transbronchial biopsy in the diagnosis of pulmonary infiltrates in immunocompromised patients. Chest 1995;107:101–106.
41 Cadranel J, Gillet-Juvin K, Antoine M, et al: Site-directed bronchoalveolar lavage and transbronchial biopsy in HIV-infected patients with pneumonia. Am J Respir Crit Care Med 1995; 152:1103–1106.
42 O'Brien JD, Ettinger NA, Shevlin D, et al: Safety and yield of transbronchial lung biopsy in mechanically ventilated patients. Crit Care Med 1997;25:440–446.
43 Fireman E: Induced sputum: Opening a new window to the lung. Sarcoidosis Vasc Diffuse Lung Dis 2001;18:263–271.
44 Olivieri D, D'Ippolito R, Chetta A: Induced sputum: Diagnostic value in interstitial lung disease. Curr Opin Pulm Med 2000;6:411–414.
45 Poletti V, Romagna M, Allen KA, Gasponi A, Spiga L: Bronchoalveolar lavage in the diagnosis of disseminated lung tumors. Acta Cytol 1995;39:472–477.
46 Bonaccorsi A, Cancellieri A, Chilosi M, Trisolini R, Boaron M, Crimi N, Poletti V: Acute interstitial pneumonia: Report of a series. Eur Respir J 2003;21:187–191.
47 Ambrosini V, Cancellieri A, Chilosi M, et al: Acute exacerbation of idiopathic pulmonary fibrosis: Report of a series. Eur Respir J 2003; 22:821–826.
48 Carson KF, Williams CA, Rosenthal DL, Bhuta S, Kleerup E, Diaz RP, Sykes E: Bronchoalveolar lavage in a girl with Gaucher's disease. A case report. Acta Cytol 1994;38:597–600.
49 White DA, Smith GJ, Cooper JA Jr, Glickstein M, Rankin JA: Hermansky-Pudlak syndrome and interstitial lung disease: Report of a case with lavage findings. Am Rev Respir Dis 1984; 130:138–141.
50 Andersen HA, Fontana RS, Harrison EG Jr: Transbronchoscopic lung biopsy in diffuse pulmonary disease. Dis Chest 1965;48:187–192.
51 Poletti V, Patelli M, Ferracini R, Simonetti M, Spiga L: Transbronchial lung biopsy in infiltrative lung disease. The importance of the pathologic approach. Sarcoidosis 1988;5:43–50.
52 Coleman A, Colby TV: Histologic diagnosis of extrinsic allergic alveolitis. Am J Surg Pathol 1988;12:514–518.
53 Lacasse Y, Fraser RS, Fournier M, Cormier Y: Diagnostic accuracy of transbronchial biopsy in acute farmer's lung disease. Chest 1997;112: 1459–1465.
54 Descombes E, Gardiol D, Leuenberger P: Transbronchial lung biopsy: An analysis of 530 cases with reference to the number of samples. Monaldi Arch Chest Dis 1997;52:324–329.
55 Poletti V, Cazzato S, Minicuci N, Zompatori M, Burzi M, Schiattone ML: The diagnostic value of bronchoalveolar lavage and transbronchial lung biopsy in cryptogenic organizing pneumonia. Eur Respir J 1996;9:2513–2516.
56 Drent M, Du Bois RM, Poletti V: Recent advances in the diagnosis and management of nonspecific interstitial pneumonia. Curr Opin Pulm Med 2003;9:411–417.
57 Watanabe K, Higuchi K, Ninomiya K, et al: Steroid treatment based on the findings of transbronchial biopsy in idiopathic interstitial pneumonia. Eur Respir J 2002;20:1213–1219.
58 Curley FJ, Johal JS, Burke ME, Fraire AE: Transbronchial lung biopsy: Can specimen quality be predicted at the time of biopsy? Chest 1998;113:1037–1041.
59 Loube DI, Johnson JE, Wiener D, Anders GT, Blanton HM, Hayes JA: The effect of forceps size on the adequacy of specimens obtained by transbronchial biopsy. Am Rev Respir Dis 1993;148:1411–1413.
60 Becker HD, Shirakawa T, Tanaka F, Muller KM, Herth F: Transbronchial (transbronchoscopic) lung biopsy in immunocompromised patient; in Strausz J (ed): Pulmonary Endoscopy and Biopsy Techniques. Eur Respir Monogr 1998, vol 3, pp 193–208.
61 Mullins D, Livne M, Mallory GB Jr, Kemp JS: A new technique for transbronchial biopsy in infants and small children. Pediatr Pulmonol 1995;20:253–257.
62 Chilosi M, Poletti V, Zamo A, et al: Aberrant Wnt/beta-catenin pathway activation in idiopathic pulmonary fibrosis. Am J Pathol 2003; 162:1495–1502.
63 Trisolini R, Lazzari Agli L, Cancellieri A, et al: The value of flexible needle aspiration in the diagnosis of stage I sarcoidosis. Chest 2003; 124:2126–2130.
64 Rena O, Casadio C, Leo F, et al: Videothoracoscopic lung biopsy in the diagnosis of interstitial lung disease. Eur J Cardiothorac Surg 1999;16:624–627.
65 Stammberger U, Steinacher C, Hillinger S, Schmid RA, Kinsbergen T, Weder W: Early and long-term complaints following video-assisted thoracoscopic surgery: Evaluation in 173 patients. Eur J Cardiothorac Surg 2000;18:7–11.
66 Daniil Z, Gilchrist FC, Marciniak SJ, Pantelidis P, Goldstraw P, Pastorino U, du Bois RM: The effect of lung biopsy on lung function in diffuse lung disease. Eur Respir J 2000;16:67–73.
67 Gaensler EA, Carrington CB: Open lung biopsy for chronic diffuse infiltrative lung disease. Ann Thorac Surg 1980;30:411–425.
68 Westein L: Sensitivity and specificity of lingular segmental biopsies of the lung. Chest 1986; 90:383–386.
69 Miller RR, Muller NL, Evans KG, Ostrow DN: Lingular and right middle lobe biopsy in the assessment of diffuse lung disease. Ann Thorac Surg 1987;44:269–273.

Downloaded from http://karger.com/res/article-pdf/71/2/107/3505852/000076670.pdf by RWTH Aachen University user on 06 March 2026